

# Zika virus might damage vision

By Sandee LaMotte, CNN

Updated 2:08 PM ET, Thu February 11, 2016

**(CNN)** Zika may now be linked to serious eye abnormalities that could lead to blindness in Brazilian newborns with microcephaly, according to a study published in JAMA including retinal and inner ear lesions.

"These are severe retina lesions that will impede the ability of the children to see well," said lead author Rubens Belfort Jr., head professor of ophthalmology at the Federal University of Sao Paulo in Brazil. "Many of these children could be blind."

## Growing concerns as researchers battle Zika virus

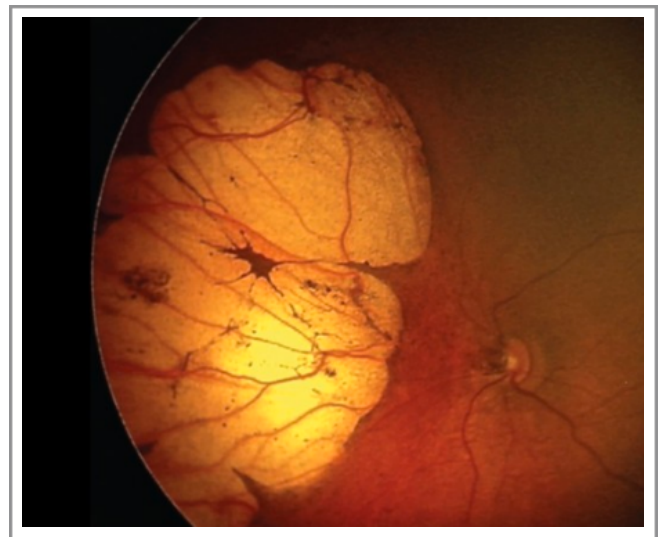
Microcephaly is a birth defect defined by an abnormally small head. Depending on the severity of the disorder and the part of the brain affected, babies who live with the defect often have developmental issues, as well as hearing and vision problems. However, **experts say that does not explain the findings from Brazil.**

"Over 35% of the babies tested showed signs of **scarring from an active viral infection in the eye.** That's much different from what would be associated with poor eye development in a microcephaly brain," said ophthalmologist Lee M. Jampol, of Northwestern University, who wrote a corresponding commentary for JAMA. "It's much more similar to what we've seen in the past with Ebola and West Nile virus."

"It provides evidence that the effects of Zika are not limited to the brain," said Yale Professor of Epidemiology and Medicine Dr. Albert Ko, who is also co-author on the study.

### Scarring could lead to blindness.

Researchers evaluated babies born with heads smaller than 32 centimeters over 21 days in December at Roberto Santos General Hospital in Salvador, one of the hardest hit areas in Brazil. All the babies were screened for other diseases that can cause microcephaly, such as toxoplasmosis, rubella, cytomegalovirus, herpes simplex virus, syphilis, and HIV. All but six of the mothers had shown signs of Zika infection during their pregnancies; **however, four out of five people with Zika have no symptoms.**



Small, dark, oblong spots dot the eye of this 1-month-old Brazilian boy born with microcephaly.

Two major scarring patterns were found in the eyes of the babies. One showed a pattern of small, dark, oblong spots in the macula, the area of the retina critical for vision; another showed intensive retinal lesions, some of which were quite large.

"When those are found in the seeing areas of the retina that will really affect the baby's future ability to see," said Jampol, "and those images show that sort of damage. **That's what a virus infection looks like when it heals up.**"

Researchers also found damage to the optic nerve, which delivers visual signals to the brain to be analyzed and "seen." "Because the lesion is at the portion of the optic nerve that is inside the eye," said Belfort, "we know that it was caused by a virus and is different than what might occur in a brain that doesn't develop properly."

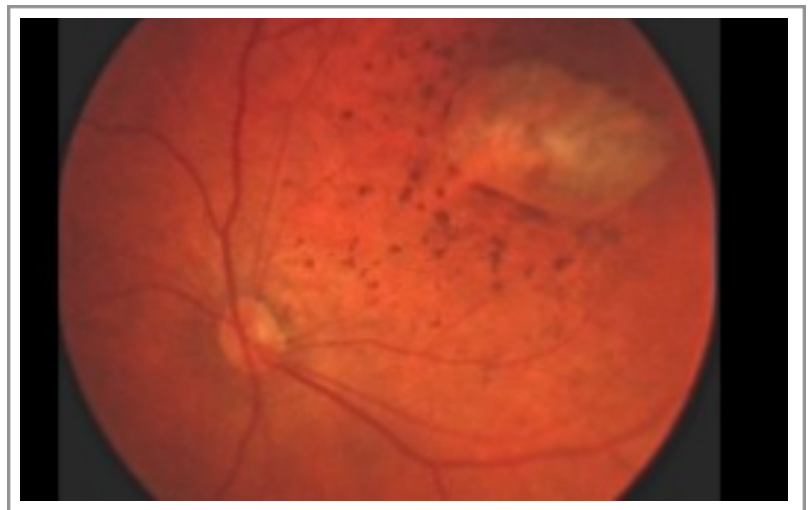
**"Is the virus still there? We don't know the answer,"** said Jampol. "Could there be a reaction in the future? We don't know the answer to that either. This is a very important study showing us that retina damage is done but much more work needs to be done." Every infant needs a retinal exam.

Researchers believe the study highlights the need for all infants potentially exposed to Zika to have a retinal eye exam, no easy feat in many parts of Latin America, where access to health care professionals trained in eye disease is limited.

"The frequency and severity of the lesions makes it important every newborn suspected of Zika infection to have the the back of the eye examined by an ophthalmologist," said Belfort. "It is possible some newborns that were infected by Zika and born without microcephaly could have ocular lesions."

### **Zika virus victims: Children born with disorders**

Yale's Ko agreed, especially in light of cases that have come up since the study was written. Researchers working with mothers exposed to Zika at Roberto Santos General Hospital are finding problems in children born with normal sized heads.



A huge lesion on the retina of a 20-day-old infant born with microcephaly.

"Besides eyes, Zika is also affecting the ear, (causing) auditory lesions, and we're worried about more than babies with small heads," said Ko. "We've seen lesions of a congenital infection in babies in normal size heads, so we're also worried that infection in utero may have downstream important impacts on cognitive developments and other issues."

"The study suggests that we may need to be on the watch for such lesions in newborns who don't have microcephaly but whose mothers may have been exposed to Zika during pregnancy," Ko added.